

Isolated, abdominal Perfusion with Chemofiltration in the treatment of progressive stage IV gastric cancer.

A. Sendler and K. R. Aigner

Medias Klinikum, Surgical Oncology, Burghausen, Germany

Background: Treatment of patients (pts.) with progressive stage IV gastric cancer remains a therapeutical challenge. Survival of the pretreated pts. is low and the therapeutic options are sparse. In this situation, locoregional therapeutic strategies could be an option.

Methods: 28 pretreated pts. (17 male, 11 female, mean age 59 y.) after resection and at least second line systemic chemotherapy were included in a phase II study of isolated abdominal perfusion and subsequent chemofiltration. All pts. had liver metastases (mets.), 50% (n = 14) had peritoneal carcinomatosis with malignant ascites. No pat. had cerebral, pulmonal or bone mets.. After insertion of a venous and arterial 21 ch. stop flow catheter (Dispomedica, Hamburg, Germany) via a femoral access, the v. cava was blocked beneath the right atrium, the arterial catheter was blocked above the celiac trunk. The thighs were blocked by pneumatic cuffs (Figure 1 and 2a,b).

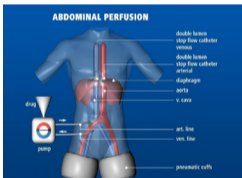


Figure 1. Scheme of isolated abdominal chemotherapy, hypoxic perfusion and chemofiltration

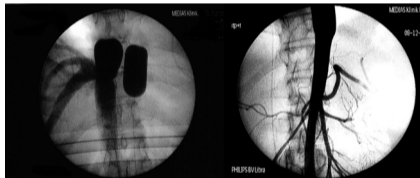


Figure 2 a and b.: Cavography and Aortography after placement of the stop-flow catheters

Chemotherapy consisted of 35 mg/m² cisplatin, 20 mg/m² adriamycin and 12 mg/m² mitomycin q 3 weeks till progress or dead. The agents were administered via the arterial access, followed by 15 min of hypoxic abdominal perfusion via an external pump, followed by chemofiltration for 45 min. The procedure was done under general anaesthesia. Primary endpoint of the study was overall survival, secondary endpoint was control of the ascites.

Reference: Aigner, KR, Stephens, FO, eds. Induction Chemotherapy, Springer Verlag, 2011; www.medias-klinikum.de; a.sendler@medias-klinikum.de

Results: A total of 92 cycles (mean 3.25) were administered. Toxicity was low with leucopenia CTC grad I in 9 pts., gastrointestinal disorders grad II in 8 pts. and surgical complications grad II in 40 % of the pat. (lymphatic fistula, Table 1).

In 9/14 (65%) of pts. with ascites, the ascites was at least controlled or vanished. One year survival was 28.6% (Kaplan-Meier), 2 year survival was 11.4%. Median survival was 6 months.

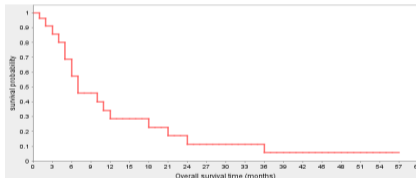


Figure 3.: Kaplan-Meier estimate after start of regional CTx in metastatic gastric cancer. 1-year survival is 29%, Median survival is 6 month.

Hematological	< 10%
Gastro-intestinal	< 10%
Surgical (lymphatic fistula)	35%
Renal	8%
No grade III or IV toxicity was observed.	

Table 1: Toxicity and surgical complications after isolated abdominal perfusion (n = 28), CTC grade I and II

Conclusion: Intraarterial, isolated abdominal perfusion with consecutive chemofiltration in heavily pretreated patients with gastric cancer metastasized to the abdominal cavity is a valuable option for palliative treatment with low side effects.

In 65% of the affected pts., malignant ascites was controlled sufficiently, ameliorating their quality of life.